SN Computer Science (2025) 6:819
https://doi.org/10.1007/s42979-025-04361-y

ORIGINAL RESEARCH

Early Detection and Severity Classification of Diabetic Retinopathy Using Convolutional Neural Networks

S. A. Karthik[1] · M. N. Geetha[2] · K. Prabhavathi[3] · Dhananjaya Shashank[4] · K. P. Suhaas[4] · M. Narender[4]

Received: 23 June 2025 / Accepted: 1 September 2025
© The Author(s) 2025

Abstract

Diabetic retinopathy (DR) has become a leading cause of blindness, and detection of the condition at an early stage is important for successful treatment. Nonetheless, it is quite difficult to detect DR in its initial stages in areas with a lack of medical care. This research seeks to develop a neural network that will have the ability to (1) detecting the presence or absence of DR, (2) early, detection (3) classification of severity of DR. We used the APTOS DR dataset that contains 3681 fundus images with DR ratings from 0 (no DR) to 4 (severe proliferative DR). Three distinct models were trained: a binary classifier, an early detector, and a severity classifier that use a neural network with three convolutional layers, a global average pooling layer, and three fully connected layers. The models were cross-validated, with a fivefold used, tracking the training and validation accuracy. The binary classifier was able to have a validation accuracy of 96.2% and an AUC of 0.992, which is higher than existing models in the literature. Early detector managed to have 86% accuracy but had difficulty distinguishing between early and severe DR. The accuracy of the severity classifier was 79.4%, being very successful in detecting healthy subjects but failing to classify more severe cases, possibly because of the model's inability to discriminate against slight differences between later DR degrees. Such results show the effectiveness of the NN usage in the diagnostics of DR and its classification, but still, more work is required for better severity prediction.

Keywords Diabetic retinopathy · Deep learning (DL) · Neural networks · Fundus imaging · Early disease detection · DR severity classification · APTOS dataset · Binary classification

Introduction

Diabetic retinopathy (DR) is a sight-threatening disease of the eye in which the light-sensitive tissue at the back of the eye, the retina, is damaged by provoked changes in the blood vessels It is a diabetes mellitus complication that is common to subjects who have had the condition for a long time, poorly controlled blood glucose. After a certain period of time, high levels of sugar in the blood can harm small retinal vessels causing leakage, swelling, and even new blood vessels formation. Irreversible vision loss or complete blindness may occur later if this harm is not diagnosed and treated. Diabetic retinopathy (DR) is one of the leading causes of vision impairment and blindness,

✉ S. A. Karthik
karthik.sa@manipal.edu

M. N. Geetha
geetha.mn@vvce.ac.in

K. Prabhavathi
pdevimtech@gmail.com

Dhananjaya Shashank
shashank@nie.ac.in

K. P. Suhaas
kpsuhaas@gmail.com

M. Narender
narender@nie.ac.in

1 Manipal Institute of Technology Bengaluru, Manipal Academy of Higher Education, Manipal, India

2 Department of Electronics and Communication Engineering, Vidyavardhaka College of Engineering, Mysuru, Karnataka, India

3 Department of Electronics and Communication Engineering, BGS Institute of Technology, B G Nagara, Mandya, Karnataka, India

4 Department of Information Science and Engineering, The National Institute of Engineering, Mysuru, Karnataka, India

Published online: 12 September 2025

especially among working-age adults worldwide. Based on global health, out of 285 million people living with diabetes, about one-third have clinical evidence for diabetic retinopathy, and of these, about one-third have vision-threatening stages, such as severe non-proliferative DR or proliferative DR, respectively [1, 2].

Its asymptomatic nature in the early stages is one of the significant issues about DR. People may not exhibit any observable vision problems until there is already a lot of damage to it. Early symptoms, if occurring, can be blurred vision, dark spots, or change in vision. The symptoms become severe as the disease advances, causing possible permanent blindness in cases of failure to detect them on time. Early detection of DR, critical for good prognosis, relies on professionals and can be labor and time-intensive. This puts certain demographics at a severe disadvantage. DR screening methods are also dependent on the subjective reading of fundus images, which leads to inconsistency in diagnosis. Thus, automatic computer-based techniques to diagnose DR are critical in the modern world [3, 4].

Diabetic Retinopathy (DR) is a kind of progressive eye disease and a leading cause of loss of eyesight among diabetic patients. Early detection and proper assessment of the level of DR is important for prompt intervention and a way of preventing blindness that cannot be reversed. Conventionally, the diagnosis of DR involves human effort through manual inspection of the fundus of the retina using medical experts, thereby taking much time, subjective, and unreliable in faced with regions that have few ophthalmologists. To overcome these challenges, there is an increasing demand for automated, reliable, and efficient diagnostic systems that can diagnose whether DR is present at early stages and determine the severity of this eye disease with high performance. Conventional automated methods tend to limit their scope to the binary classification and have minimal efficacy in distinguishing early and advanced stages of the disease.

Although significant improvements have been made using deep learning in diabetic retinopathy (DR) detection, there are still significant challenges to the existing approaches. Existing works design separate models that perform binary detection, early diagnosis or severity grading, leading to disjointed frameworks and mixed performance across tasks. Additionally, the availability of public data like APTOS is very unbalanced with severe and progressive cases that are severely under-represented and results in poor generalization of the most severe forms of the disease. Lastly, most current deep architectures are black-boxed models with low interpretability, limiting their consideration in the clinical setting. These gaps point to the necessity of a unified, effective, and explainable approach to automated DR detection.

This study can be motivated by the need to provide a practical diagnostic framework to fix the deficiencies of the current models. The redundancy and lack of consistency can be addressed by a single unified CNN architecture that performs a binary classification, early-stage detection, and multi-class severity grading. The combination of the class weighting and targeted augmentation techniques will enable the model to effectively address the issue of dataset imbalance by better detecting the cases of advanced DR. Besides, visual analysis using Grad-CAM makes the system more acceptable to clinicians due to its interpretability. The lightweight CNN generates a good trade-off between precision and computing complexity comparable to its deep architecture counterparts and hence is an appropriate candidate to be applied in practical depleted source-rubbing clinical settings.

The novelty of this work lies in the design of a unified lightweight CNN framework capable of performing three critical DR diagnostic tasks—binary classification, early-stage detection, and five-class severity grading—within a single modular architecture. Unlike prior studies that build separate or deeper models, our approach:

1. Employs a shallow CNN (4 conv layers + GAP + FC layers) that achieves competitive performance while remaining computationally efficient for low-resource clinical settings.
2. Integrates class weighting with targeted augmentation (CLAHE, brightness/contrast modulation, rotations) to mitigate dataset imbalance, particularly for severe and proliferative DR classes.
3. Provides explainability through Grad-CAM heatmaps, enabling clinical interpretability of model decisions.
4. Demonstrates a superior trade-off between accuracy (96.2% binary, 86% early detection) and model complexity, showing effectiveness without reliance on very deep networks or massive private datasets.

This manuscript has been divided into different sections. "Related Works" section is a study of different available related works and models that have been earlier proposed for loopholes identification in early DR detection. "Proposed Methodology" section presents a detailed representation of the proposed methodology and identifies the relevance of DL models when it comes to improved feature extraction and classification. The results for proposed DL models are shown in "Results and Discussion" section, which demonstrates the results based on the analysis and comparison of the performances of the models. "Discussion" section comes to a point where the appropriate DL architecture(s) for the purpose of DR detection is indicated.

Related Works

Recent advances in artificial intelligence have significantly improved the early detection and severity classification of Diabetic Retinopathy (DR), leveraging deep learning and machine learning techniques across various studies.

Firmansyah et al. [5] used Convolutional Neural Networks (CNNs) to design a system that can detect Diabetic Retinopathy (DR) early and identify its severity as well. It achieved results of up to 97% accuracy and aimed to boost screening by automating the process. The system allows medical staff to respond quickly and reduce the chance of diabetic patients having vision problems. Ainapur and Patil [6] suggested using a Conjugated Attention Mechanism and a Vision Transformer in the Collective Net model. The model was run on several well-known data sets and reported an accuracy of 99.63% percent. Using this model, DR and how severe it is can be detected and assigned at an early phase in clinics. Saritha et al. [7] designed an AI-based system that uses machine learning to help diagnose DR using fundus images. The new system managed to address the issues with manual screening by integrating automatic feature detection, leading to improved patient care and consistent medical procedures. Sugathan et al. [8] developed a CNN-based system to assign one of five severity levels to each of the 2,000 fundus images in their dataset. This study found that with a 79.49% accuracy, deep learning models play an important role in spotting the disease early, helping start treatment early and stopping the disease from spreading. In their study, Bouslimi et al. [9] used data from APTOS 2019 and DRD retinal photographs after pre-processing them all together. Before the data was used, it went through augmentation, resizing, balancing, and Gaussian filtering. Various deep learning networks, such as ConvXLarge, ResNetRS101, ResNetRS270, and ResNetRS420, were examined. ResNetRS101 was the best performer, with 93% test accuracy, proving that using deep networks helps organize images into stages of DR. Negi et al. [10] looked into the prospects of using CNNs and Generative Adversarial Networks (GANs), with the aid of deep learning, for detection of DR in the early stages. When compared to old approaches, they showed improved performance and better capabilities for DR classification. DenseNet201 with transfer learning was used by Sathvika et al. [11] to develop a DR classification model. A model was built using images of 9,573 patients, and it achieved 73% accuracy. It was clear from the study that pre-trained models give the best results when data is not as widely available in medical imaging.

Manasa et al. [12] came up with a machine learning framework powered by SVM, logistic regression, random forest, and Naive Bayes. It used a processing approach, extracted useful information from the data, and included explainable AI methods, which made the detector simple to understand and use for diagnosis. ResNet50, a deep CNN model, was used by Hasan et al. [13] to classify the gravity of DR in both retina fundus and thermal images. Relying on thermal imaging made it possible to examine the body in more detail and detect symptoms early, helping with efficient treatment. The paper by Sangeetha et al. [14] examined how automated machine learning can be applied using images from fundus and Optical Coherence Tomography (OCT) to discover DR cases. They found that the results from the new methods were more accurate and quicker than the usual manual examinations by ophthalmologists. Siyah et al. [15] compared the performance of VGG16, ResNet50, and MobileNetV2 in the classification of DR. Paying attention to microaneurysms and hemorrhages in their models allowed them to achieve high accuracy in determining the stages of DR. Pasha and Rajashekar et al. [16], came up with a Resemblance Pixel Vector Set-Convolutional Neural Network (RPVS-CNN) model. With this system, automated detection and grading of DR made it easier for doctors to diagnose patients and use less help from experts. Uppamma and Bhattacharya et al. [17] suggested a bio-inspired ensemble model that brings together several features from images of the eye. By bringing together several classifiers, they managed to achieve an accuracy of 96.5% and make severity classification more reliable. Deep learning architectures based on VGG16 and XGBoost and on DenseNet121 were developed by Vandana and Vijay Laxmi et al. [18]. The results show that combining feature extraction with gradient boosting, as done in both hybrid and DenseNet models, brought an accuracy of 79.50% and 97.30%, respectively. Balogun et al. [19] tested a custom CNN alongside SVM and KNN for the classification of DR. CNN had a 92% accuracy rate which was more accurate than KNN (86%) or SVM (66%). Nguyen et al. [11] designed an automatic classification model that uses CNN and the VGG16 and VGG19 architectures. While labeling DR from 'no DR' to proliferative DR, the proposed system reached 80% sensitivity and 82% overall accuracy. Team Singh et al. [20] chose to rely on transfer learning and the EfficientNetB3 model to classify multiple cases of DR. Although trained on fewer data points, the model still achieved high accuracy in each of the five severity classes and can work in real-world situations.

Parthasharathi et al. [21] introduced a neural network system that focuses on identifying exudates, hemorrhages, and microaneurysms in the eyes. By relying on certain features, it was easy to assess the severity and match the findings with clinical evaluation. Nawaz et al. [22] employed deep learning and transferred learning using Inception-v4 for work on DR detection. Detections and evaluations using this model

were very precise, with 96.6% and 97.7% accuracy, much higher than what other approaches have managed. The group led by MZ Atwany assessed the recent use of deep learning approaches for DR detection and classification [23]. They looked at both pathologies of the retina that can be compared and those that cannot, plus the progression stages, highlighting that deep learning tools in retinal imaging are improving and becoming more useful for doctors. A research team led by Mohanty [24] suggests two architectures for deep learning: a combo of VGG16 and XGBoost achieved 79.50% accuracy, and a DenseNet121 network reached 97.30% accuracy. There were noticeable improvements in diagnosing patients in areas where resources are limited. Researchers Ahmad et al. [25] proposed a modified CNN model to identify the early onset of DR on benchmark photos. Because it demonstrated excellent accuracy in grading disease severity, the framework played a role in automating screening for many people. Sushith et al. [26] proposed an hybrid approach which merges CNNs and RNNs to detect and oversee changes in DR using fundus retinal images. The model's use of the progression sequence of different scans increases its ability to detect diseases. CNNs were chosen to get spatial features on the DRIVE and Kaggle DR datasets for the evaluation of the framework. Senapati et al. [27] noted recent progress in AI-based DR diagnosis and stressed how ML and DL help improve diagnosis. The study found that, even though there have been good results, problems like complicated calculations, inequality in datasets, and the ongoing cost of maintenance remain. Authors called for better and more accurate approaches to aid early-stage detection of DR.

Jabbar et al. [28] introduced a way to find and detect DR in real time, using fundus images and training VGG-Net algorithms. The images from the retina were used to rate the severity of the disease and create precise reports that aided medical decisions. The system proposed here obtained higher accuracy in classifying images than the earlier techniques. Arora et al. [29] introduced a classification method that uses the EfficientNetB0 architecture to determine DR severity. The use of CNN-based layers and machine learning in the model was intended to boost the reliability and accuracy of diagnosis. The test results showed that the framework does improve diagnostic performance, hence making it useful in clinical work. Alavee et al. [30] investigated the classification accuracy of transfer learning methods such as DenseNet121, Xception, ResNet50, VGG16, VGG19 and InceptionV3, as well as conventional ML models like SVM and RNNs, on DR images. It was found that their approach using softmax and categorical cross-entropy helped the model achieve excellent accuracy, precision, and recall on the data. Liaqat et al. [31] suggested a DR classification method using Google Net and ResNet architectures, which were optimized with an adaptive particle swarm optimizer (APSO). After extracting features using a hybrid model, these features were classified with ML algorithms like random forest, SVM, decision tree, and linear regression, helping to ensure both reliability and ease of understanding in the system. Rajeshwar et al. [32] developed a hybrid system combining image processing methods and ML classifiers for DR diagnosis. Data was augmented, images were processed in various steps, and ResNet50, InceptionV3, and VGG19 were used for feature extraction. By combining DT, KNN, SVM, and a modified CNN with spatial attention, the results showed greater accuracy in cancer detection.

Kommaraju et al. [33] proposed DRCNNRB, a CNN with residual blocks that leverage standard augmentation (zooming, rotation, flipping) to handle the class imbalance in the prediction of DR severity. Sushith et al. [26] developed a CNN-RNN hybrid that uses temporal data to take into consideration sequential retinal scans to improve early diagnosis and monitoring of progression using the DRIVE and Kaggle datasets. On Messidor-1, RSG-Net is introduced by Akhtar et al. [34], which is a deep neural network trained with histogram equalization and data augmentation to enhance contrast and resolve imbalance of both binary and multi-class DR grading tasks. Subsequently, Muthusamy et al. [35] proposed MAPCRCI-DMPLC, in which the pool of filtered features and the ROI are obtained by MAP estimation and the texture and color features are analyzed, and using a deep network with swish internal activation function, a high accuracy is achieved. Azzou et al. [36] suggested transfer-learning-based pipelines (AtRD, AtR3C, AtR5C) followed by Bayesian hyperparameter optimization, with model performance with three-class and five-class DR detection being consistently better with ResNet 50-based strategies. Another study, conducted by Chakraborty et al. [37], aims at early DR detection with handcrafted features (hard exudates, microaneurysms, blood vessels), comparing supervised ML models with expert optometrists. Nadda et al. [38] developed an ensemble model of CNNs (ResNet50, DenseNet121, SqueezeNet) and conventional ML (SVM, decision tree) classifiers achieving better performance on Kaggle fundus image datasets, by performing better in a stage-wise manner.

Existing studies present encouraging findings, although they have three major limitations. Most works focus on a single task, be it binary classification, early detection, or multi-class severity grading, without unifying the framework into a model that would invariably address all stages of diagnosis. Second, most methods rely on complex training architectures (e.g., ResNet, DenseNet, or ensembles), however, these methods are hard to implement in in-the-field clinical systems with severe capacity limitations. Lastly, faithfully, interpretability is yet to be thoroughly researched;

only a handful of studies have incorporated explainable AI approaches like Grad-CAM to facilitate clinically relevant validation and trust in models.

The shortcomings of existing methods are directly mitigated by the fact that the proposed approach incorporates a unified lightweight CNN model that can perform binary classification, early detection, and severity grading tasks across a single modular framework rather than requiring multiple differentially-trained models. To eliminate the bias associated with DR data, the framework incorporates class balancing and targeted augmentation strategies (CLAHE, brightness/contrast modulation, rotations) so that severe DR cases (which are relatively underdiagnosed) could be well represented. Compared to such computationally expensive deep networks and ensembles, the proposed CNN is shallow and effective, and thus, ensures a good balance between accuracy and efficiency, which makes it appropriate to be deployed in resource-limited clinical settings. In addition, the introduction of Grad-CAM visualizations promotes transparency of the model and enables clinicians to interpret predictions and justify the decision-making process, which is also not widely discussed in the existing literature.

Proposed Methodology

Figure 1 shows the proposed approach to the early detection of diabetic retinopathy (DR) with convolutional neural networks (CNNs). The overall workflow is intended to automate the process of diagnosis using a series of systematic steps that all contribute to the correct classification of the severity of DR. Beginning with the input of labeled fundus images, the process spans from the preprocessing of images, extracting features, and classification using a deep learning model. The CNN architecture plays the primary role in this approach, allowing for automatic detection of the retinal anomalies at various stages of DR. Every stage in this scheme is essential in ensuring reliable prediction and efficacious disease grading. Each step is described in detail in the next section.

Dataset

Figure 2 illustrates the class distribution within the APTOS blindness dataset [39], which is widely used for automated detection and classification of diabetic retinopathy (DR) based on retinal fundus images. The dataset categorizes DR into five classes: Class 0 (No DR), Class 1 (Mild DR), Class 2 (Moderate DR), Class 3 (Severe DR), and Class 4 (Proliferative DR), with proliferative retinopathy representing the most advanced stage of the disease. As depicted in the figure, the dataset is highly imbalanced, with a disproportionately large number of images labeled as Class 0 and Class 1, while Classes 3 and 4 are significantly underrepresented. This skewed distribution presents a critical challenge during model training, as it may cause the model to become biased toward the majority classes, thereby reducing its ability to accurately identify and classify more severe DR cases. To mitigate this issue and improve classification performance across all severity levels, techniques such as oversampling, class weighting, or data augmentation may be required. Recognizing this imbalance is essential for designing robust deep learning models capable of generalizing well, especially in real-world clinical scenarios where accurate detection of severe DR is crucial for timely intervention.

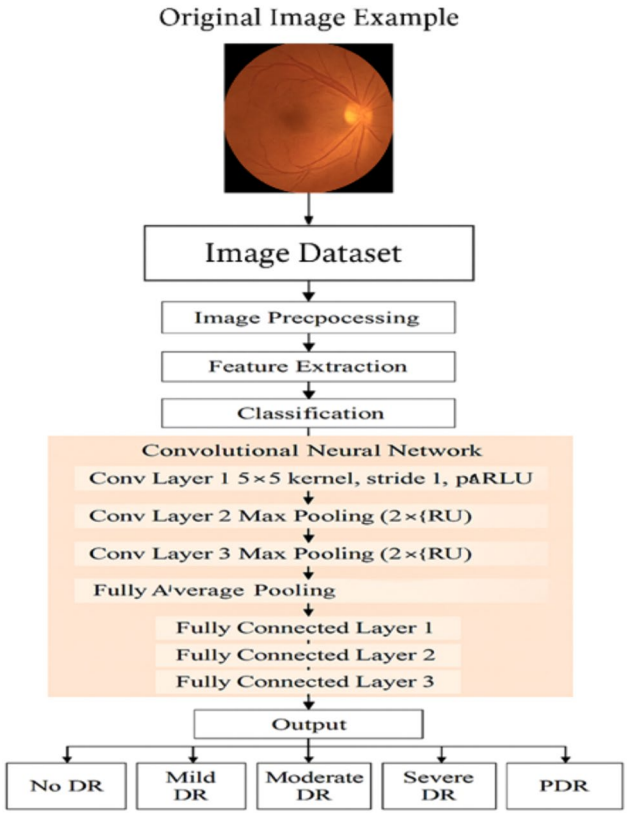

Fig. 1 Overall workflow of the proposed CNN-based DR severity classification framework, including preprocessing, feature extraction, and classification

The experiments were implemented with the publicly available dataset of APTOS 2019 Blindness Detection provided by Kaggle and contained high-resolution retina fundus photographs taken under different imaging conditions. The grading of each of the images is done by the ophthalmologists into 5 severity grades of diabetic retinopathy (DR): Grade 0-No DR, Grade 1-Mild, Grade 2-Moderate, Grade 3-Severe, and Grade 4-Proliferative DR. This scale of grading is consistent with the International Clinical Diabetic Retinopathy (ICDR) scale, which provides clinical nature to the data that can be used to benchmark automated screening

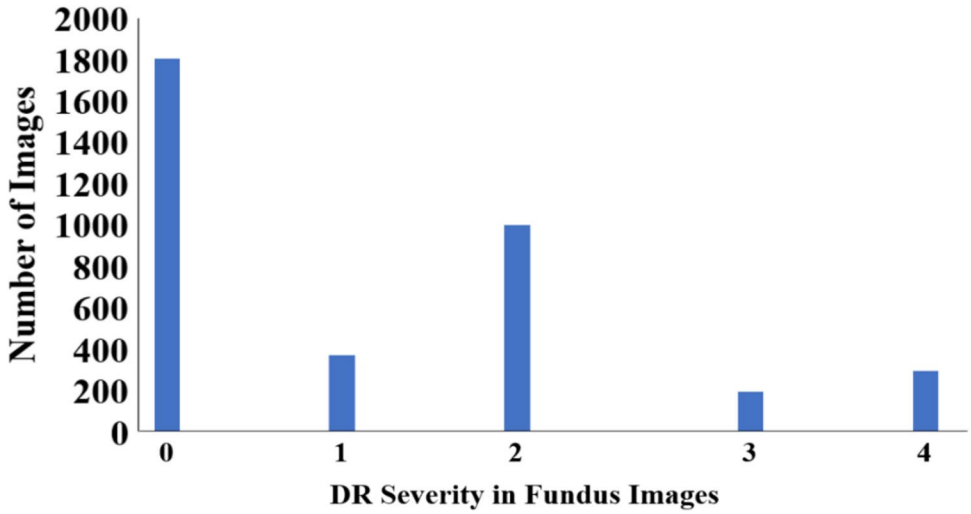

Fig. 2 Distribution of image classification in the APTOS blindness dataset

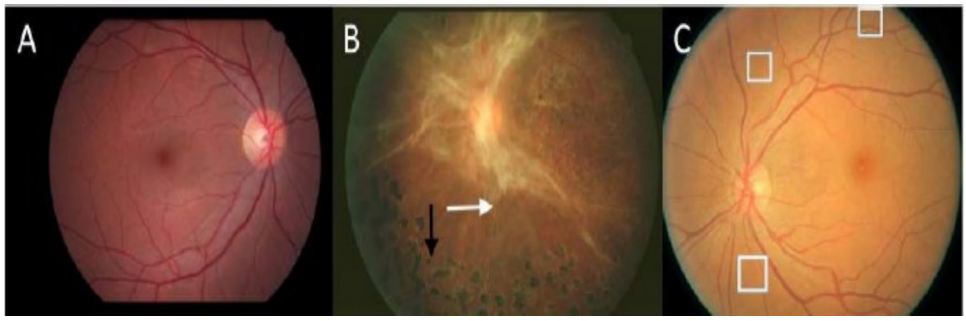

Fig. 3 **A** Normal fundus photograph, **B** severe DR with white arrows pointing towards flame shaped hemorrhages, **C** early stage DR with white boxes showing micro-aneurysms

systems. A total of 3,662 color fundus images were shown in this research. As the classification task is imbalanced, a thoughtful data-split pattern was adopted to ensure the presence of unbiased performance estimation. Part of the dataset was cancelled into a training, validation and test set by 70%—15%—15% factor with stratified sampling, which means that this proportion of every DR category was maintained throughout the splits. This enabled the model to be trained on a representative set, tuned on balanced validation data, and reasonably evaluated on independent test data that translates into a real-world class imbalance.

Figure 3 illustrates various stages of diabetic retinopathy (DR) using fundus photographs. Panel A is a normal fundus photograph with a healthy retina, having no retinopathy signs. Panel B shows advanced DR, identified by white arrows that indicate flame-shaped hemorrhages—characteristic of the advanced stage when blood vessels burst and bleed, which are common in proliferative diabetic retinopathy. Panel C demonstrates early-stage DR, micro-aneurysms (white boxes), small bulges in retinal blood vessels, and one of the first who suffer from the disease. These pictures convey the development of DR from having no abnormalities to more significant damage in the advanced stages.

Table 1 provides the details of the class distribution in the APTOS 2019 Blindness Detection dataset. The data provide a total of 3,662retinal fundus images with five severity levels of diabetic retinopathy (DR) in the International Clinical Diabetic Retinopathy (ICDR) scale. Almost half (49.3%) of the samples represents healthy cases, i.e., Class 0 with no DR. The proportion of Mild DR (Class 1) is 10.1 and Moderate DR (Class 2) 27.3 which makes it the second largest group. This distribution gets quite sparse in the more advanced stages as Severe DR (Class 3) is confined to 5.3% of the dataset and Proliferative DR (Class 4) to 8.1%. This biased distribution illustrates the existence of a considerable imbalance in classes, with early-stage and healthy cases being strongly overrepresented in comparison to the later,

Table 1 Class distribution in the APTOS 2019 blindness detection dataset

Class	DR severity level	Number of images	Percentage (%)
0	No DR	1805	49.3
1	Mild DR	370	10.1
2	Moderate DR	999	27.3
3	Severe DR	193	5.3
4	Proliferative DR	295	8.1
Total	–	3662	100

more clinically dangerous ones. This imbalance presents problems in training deep learning models since they can be biased to the majority classes. To overcome this, we combined class weighting and focused data augmentation (e.g., CLAHE, rotation, flipping, brightness/contrast manipulation, zooming) to better capture the minority classes and the capability of our model in detecting severe and proliferative DR.

Preprocessing

A preprocessing pipeline was established to improve the image quality and achieve consistency in the dataset, prior to training the CNN. All retinal fundus images were resized to 224 × 224 pixel dimensions to fit the input requirements of the proposed model and to facilitate the reduction in computation load without losing vital structural content. To stabilize the optimization process and speed up convergence during training, pixel intensity normalization was used, by scaling values to the range [0,1].

Fundus images may be characterized by poor illumination, shades, and intensities that vary, it is highly recommended that Contrast Limited Adaptive Histogram Equalization (CLAHE) be used. LAHE adaptively boosts local contrast without amplifying noise excessively, thus leading to retinal details (e.g. blood vessels, microaneurysms and hemorrhages) becoming more discernible. Moreover, Gaussian filtering was performed to reduce high-frequency noise and to smooth image artifacts without substantially blurring those high-frequency structure which are of diagnostic importance.

Additionally, extreme cases of blur, underexposure, or overexposure were detected and removed by visual inspection to maximize the quality of training inputs used during training. In order to ensure that the final dataset preserved a significant level of fine-grained pathological details such as exudates, microaneurysms, hemorrhages, and abnormalities of blood vessels that are all unique characteristics of DR cases, necessitating precise interpretation and labeling of the severity of the disease, a multi-stage automated preprocessing pipeline was used.

Dataset Modifications

The APTOS dataset [40] was used to run three experiments:

1. Binary classification
2. Early detection
3. Severity classification

At the beginning, all the retinal fundus images were scaled down to 256 × 256 pixels so the input dimensions would be the same for every image and model training would be easy. Standardizing the pixel values to be between 0 and 1 made the image easier to process and quicker to train. All RGB color channels were kept in the process of preprocessing to make sure color details in retinal photos were not lost, as these details help discover the mild lesions and vascular problems connected to different stages of diabetic retinopathy. Preprocessing the data like this helps ensure that CNN input is standardized and high quality which results in better and more accurate extraction and classification of features. This architecture also uses a series of convolutional, pooling and fully connected layers on the preprocessed images to generate the outcome which covers five DR levels: No DR, Mild DR, Moderate DR, Severe DR and Proliferative DR (PDR). For the first model (binary classifier), the image labels were changed to “0” if the image had no DR, or “1” otherwise. For the second model (early detector), images with no DR were labelled “0,” “1” if they had early DR (corresponding to “1” and “2” from original dataset), or “2” if they had severe DR (corresponding to “3” and “4” from original dataset). For the final model (severity classifier), the original labels were maintained.

The APTOS dataset employed in the present study is highly skewed, with Class 0 (No Diabetic Retinopathy) occupying a massive majority of the samples, and Class 3 (Severe DR) and Class 4 (Proliferative DR) being underrepresented. This bias presents significant difficulties in training deep learning models because such skews frequently cause biased learning in which a model tends to over favor the majority class and does not generalize well to all levels of severity. To overcome this challenge, the proposed work introduces two sophisticated and complementary methodologies, including class weighting and location invariant data augmentation.

Class weighting was used as weights were calculated as a fraction of the inverse of the frequencies of classes and incorporated into the cross-entropy loss term. This allowed for penalizing errors on minority classes (severe and proliferative DR) at training, thereby encouraging them to find a solution. This adaptation prompted the model to concentrate on discerning details of these peculiar and clinically important conditions, thus enhancing its sensitivity to later stages of the disease.

Simultaneously, targeted data augmentation was even used to augment the underrepresented classes to increase variation and the size of the training examples. Augmentations involved horizontal and vertical reflections, random rotations, modulation of brightness and contrast, zooming, and Contrast Limited Adaptive Histogram Equalization (CLAHE). The specific CLAHE enabled the improvement of local contrast of fundus images, allowing the detection of fine pathological details such as microaneurysms, exudates, and hemorrhages. Not only did these augmentations alleviate the scarcity of severe DR images, but they also enhanced

the robustness of the model by adding variability between intra-class samples.

The proposed CNN architecture both improved in terms of generalization across all five classes of severity by leveraging both training dynamics (class weighting) and input diversity (data augmentation). Such a balanced framework allowed a more accurate classification of early and late-stage DR, resulting in an automated and clinically practical approach to the diagnosis of diabetic retinopathy.

Feature Extraction and Model Architecture

The proposed method is capable of automatically carrying out feature extraction in the convolutional neural net (CNN) layers instead of requiring handcrafted features. The process is initiated by using convolutional layers in which a number of filters move over the input images to identify low-level features such as edges, corners and color gradients that are critical in capturing the general structure of retina. As the network goes deeper down the layers, they become increasingly abstract and complex, including patterns of blood vessels, microaneurysms, hemorrhages and exudates, which are diagnostic elements to diabetic retinopathy grading. Every convolution layer is preceded by Batch Normalization and ReLU activation, which enhance the training stability and introduce non-linearity, respectively allowing the model to learn complex associations between retinal features. Max-pooling layers are used to down sample the spatial reliability and preserve the most elevated activations, therefore, maintaining translational invariance and lowering the computing demands.

To increase generalization, dropout layers are added, which during training randomly turns off neurons. The high-level feature maps are filtered after the convolutional blocks are passed to a Global Average Pooling (GAP) layer that condiles spatial information to a compact representation devoid of the redundancy of fully connected layers. The learned features are ultimately inputted to a fully connected and dense layer with a softmax activation and is used to produce the final results in terms of diagnosis regarding the severity of diabetic retinopathy. The CNN uses hierarchical feature extraction on the backbone of pooling and normalization techniques giving richness of discriminative features; spanning micro-level anomalies (small lesions, vessel abnormalities) to macro-level structures (optic disc, macula region) that can be used to robustly detect and grade DR.

The proposed architecture in the model of diabetic retinopathy classification starts with the first Convolutional Layer (Convolutional Layer 1), where the 5×5 kernel is applied in the first layer, with the parametric ReLU (pReLU) as an activation function to identify low-level features like edges and textures of the picture of the retina. This continues with Convolutional Layers 2 and 3 that apply max pooling in reducing spatial dimensions along with boosting of the mid-level and high level features, essentially detecting the significant structures such as blood vessels, microaneurysms, hemorrhages, and exudates. A Global Average Pooling Layer is further added after these convolutional layers to compress the spatial information of the feature maps in order to form a compact feature vector so that the model may learn to reduce overfitting and better generalize. The vector is then fed through a combination of three Fully Connected Layers that successively convert the learnt features into an efficient classification process. The last layer of classification has an arbitrary number of nodes that represent an output, labeled by ~ and vary with the type of classification, e.g., binary (e.g., DR vs. Single DR) or multi-class (e.g., five levels of severity). As shown in Fig. 4, the general structure adopts a unifiable pattern in all the experimental setups and works well in reinforcing the severity annotation of diabetic retinopathy.

The detailed summary of the layer-wise architecture of implementing the diabetic retinopathy classification using the proposed convolutional neural network (CNN) model is given in Table 2. The architecture consists of four 5×5 kernel-sized convolutional layers followed by a max pooling layer in order to scale down the used spatial dimensions continuously and maintain central retinal characteristics, like microaneurysms, exudates, and hemorrhages. The spatial feature maps are down-projected into a lower-dimensional space by a global average pooling layer and then classified in three fully connected layers. The last output layer is dependent on the task and is varied in the number of nodes depending on the classification aim: 2 nodes binary classification (presence or absence of DR), 3 nodes early detection (no DR, early DR, and severe DR), 5 nodes severity classification (ranging Class 0 to Class 4). This modular design enables the reuse of a common backbone architecture with minimal adjustments, ensuring flexibility and efficiency across different classification tasks.

Algorithmic Description

The following algorithm summarizes the proposed CNN-based framework for diabetic retinopathy (DR) severity classification.

Algorithm 1 DR severity classification using CNN

Input: Retinal fundus image I

Output: Predicted severity label ŷ ∈ {0,1,2,3,4}

Steps:

1. Preprocessing

- Resize I to 224×224.
- Normalize pixel values to [0,1].
- Apply CLAHE for contrast enhancement.
- Apply Gaussian filtering for noise removal.
- Exclude severely blurred or corrupted images.

2. Data Augmentation

- Perform random rotations (±20°).
- Apply horizontal/vertical flipping.
- Adjust brightness/contrast.
- Apply zooming and shearing on minority classes.

3. Feature Extraction (via CNN)

- Apply convolution + ReLU to extract low-level features F1.
- Apply convolution + pooling to extract mid-level features F2.
- Stack convolutional blocks to extract high-level features Fn.
- Use Global Average Pooling (GAP):

  $f = (1/HW) \Sigma \Sigma Fn(i,j)$

4. Classification

- Fully connected dense layer with softmax activation:

  $P(y=c|f) = e^{zc} / \Sigma e^{zk}$, K=5

5. Output

- Predicted severity level ŷ ∈ {0,1,2,3,4}.

Determining Hyperparameters

Table 3 shows the impact of changing the important hyperparameters (that is epochs, batch size, and learning rate) on model's validation accuracy, but while maintaining the number of the training and testing images at 256. Firstly, training the model for 10 epochs, while using a batch size of 32 and a learning rate of 0.0001 gave a validation accuracy of 88%. Increasing epochs to 30 in the same configuration, the accuracy was improved to 90% and a repeated run with same configuration resulted in an accuracy of 94% which is testament to better convergence. (But) When the batch size was reduced to 16 and learning rate, which in turn was much smaller, 0.00001 accuracy, was substantially brought down to 68% as a probable underfitting. In comparison, when the learning rate was increased to 0.001, and with the same batch size an improvement in accuracy of 91% was observed which highlights the sensitivity of the model to the learning rate. Furthermore, using a smaller batch size of 8 with learning rate 0.0001 resulted up to 93% accuracy indicating that using a small batch size whilst choosing an appropriate learning rate could improve generalization. As a whole, the results outline the value of thoughtful hyperparameter tuning for improving the performance of models.

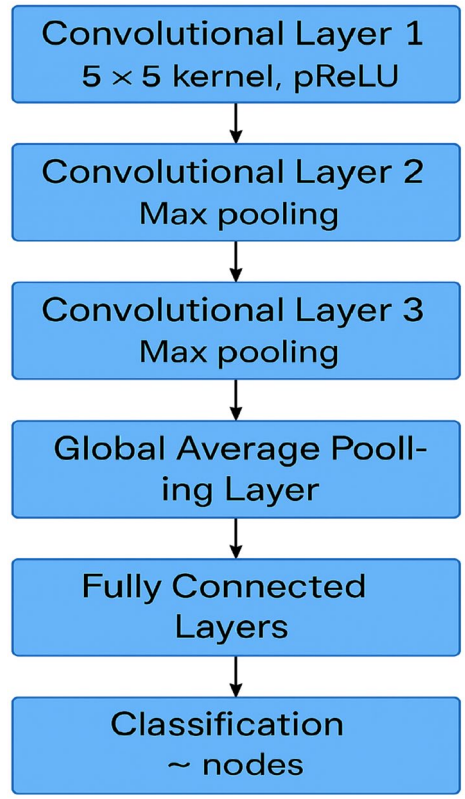

Fig. 4 General model architecture used for all three experiments. '~' in the final fully connected layer signifies that the final number of nodes changed depending on the experiment

Table 4 shows the final set of hyperparameters to be used in their respective models within the proposed diabetic retinopathy classification framework, binary classifier, early detector, and the severity classifier. The choice of these configurations was due to a lot of experimentation and validation results that have been mentioned previously. In the case of the binary classifier, the best performing batch size was 32

Table 2 Layer-wise architecture of the proposed CNN model

Layer	Type	Kernel size/Units	Activation	Output shape (for 256×256×3 input)
Input	–	–	–	256×256×3
Convolutional Layer 1	Conv2D	5×5	pReLU	256×256×32
Max Pooling Layer 1	MaxPooling2D	2×2	–	128×128×32
Convolutional Layer 2	Conv2D	5×5	ReLU	128×128×64
Max Pooling Layer 2	MaxPooling2D	2×2	–	64×64×64
Convolutional Layer 3	Conv2D	5×5	ReLU	64×64×128
Max Pooling Layer 3	MaxPooling2D	2×2	–	32×32×128
Convolutional Layer 4	Conv2D	5×5	ReLU	32×32×256
Global Average Pooling	GAP	–	–	1×1×256
Fully Connected Layer 1	Dense	512	ReLU	512
Fully Connected Layer 2	Dense	256	ReLU	256
Output Layer	Dense	~(2/3/5 nodes)	Softmax	Varies according to classification

with a learning rate of 0.0001 and 30 training epochs, possessing an excellent validation accuracy of 96.2% and robust AUC rates in all splits. The earlier model of basic detector, where they had three classes to differentiate (no DR, early DR, and severe DR), left the batch size slightly reduced to 16 and a learning rate set at 0.001, which provided a faster convergent model without compromising generalization through 40 epochs. In the more difficult task of five-class severity classification, a lower batch size of 8 and a smaller learning rate of 0.0001 were observed to perform best. This setup allowed this model to concentrate more on the less noticeable details and learn complex behaviours through 40 training epochs with an average validation rate of 79.4%. Such hyperparameter options represent a balanced approach to the aspects of training performance, model intricacy, and dataset composition, and they significantly influenced the overall performance of any of the classification exercises.

Training and Testing Protocol

A fivefold cross-validation study was performed for each experiment. Four splits were used for model training, and the final split was used for model validation. After each epoch of training, the model was immediately validated. Training loss, training accuracy, validation loss, and validation accuracy were tracked for all epochs. The actual and predicted labels were saved. For binary classification, the true positive and false positive rates were calculated for each split. For the early detection and severity classifying experiments, confusion matrices were created for each split.

Classification

The classification process comes after the feature extraction stage, and it is the process of decision making it determines the final diabetic retinopathy (DR) stage from the extracted features. The three fully connected layers then apply themselves to the fixed size vector after the average pooling layer has shrunk the spatial feature maps. These layers operate as a conventional neural network, with each neuron being connected to all the neurons in the previous layer for the model to make sense out of the complex features received at the convolutional layers.

Each of the fully connected layers applies learned weights and activation functions in order to continue to refine the decision boundary. These representations are used by the final output layer to predict the probabilities or scores that belong to each type of diabetic retinopathy. The result is divided into five categories. There are no DR, mild DR, moderate DR, severe DR and PDR. The class with the highest probability is chosen as the final prediction, and it is the severity level of DR demonstrated in an input retinal image.

Results and Discussion

Binary Classifier

Figure 5A shows that the training loss decreases approximately 89% over 25 epochs. While the training loss decreased, the validation loss also decreased for all of the splits as shown in Fig. 5B. After epoch 15, however, there seems a slight increase in validation loss. Since training loss is decreasing past epoch 15, but validation loss shows small increase, the model might be overfitting. In the future, model training would be stopped if training loss decreases, but validation loss increases.

The validation accuracy for the binary model is shown in Fig. 6A and shows that it performs well for all sets of data. Accuracy steadily gets better as training continues and ends up at high and stable levels. Because the performance is consistent on all split groups, it appears the

Table 3 Varying hyperparameters and seeing the effect on validation accuracy

Number of train images	Number of test images	Epochs	Batch size	Learning rate	Validation accuracy (%)
256	256	10	32	0.0001	88
256	256	30	32	0.0001	90
256	256	30	32	0.0001	94
256	256	30	16	0.00001	68
256	256	30	16	0.001	91
256	256	30	8	0.0001	93

Table 4 Final hyperparameter settings for each experiment

Model	Batch size	Learning rate	Epochs	Validation accuracy (Avg.) (%)
Binary classifier	32	0.0001	30	96.2
Early detector	16	0.001	40	85.2
Severity classifier	8	0.0001	40	79.4

model is able to generalize beyond the part of the data it learned.

Additionally, Fig. 6B gives the ROC curves for every split which demonstrates that the model is very reliable. The ROCs go close to the top-left corner of the plot, demonstrating that the model performs with both true and false positive rates very low and true positive high across all validation sections. The model consistently shows a high AUC, proving that it has strong ability to separate one class from the other. In combination, all of these findings prove that the binary classifier can accurately discern diabetic retinopathy from other conditions.

Table 5 provides the validation accuracy and area under the curve (AUC) values for 5 different data splits, where the model's performance is shown to be consistent on varying data sets. In split 1, the model had 0.949 validation accuracy and 0.990 AUC, which shows the accuracy of the model being high. Split 2 had the best results, as it achieved a validation accuracy of 0.971 and AUC of 0.996, which means superior classification skills. Splits 3 and 4 also demonstrated, a high accuracy of 0.968 & 0.964 and AUC of 0.992 & 0.994 respectively, strengthening the model's reliability. Split 5 had a slightly lower rate of accuracy at 0.954 and AUC value of 0.985 but still showed high performance. Generally, the average validation accuracy on all the splits was 0.961 with an average AUC of 0.992 which is an indication of the model's reliability and consistency in differentiating between classes on various validation sets.

Early Detector

Figure 7A shows that training loss dropped by more than two-thirds or about 76% during the first 40 epochs. When the trend goes down, it means the model is improving its

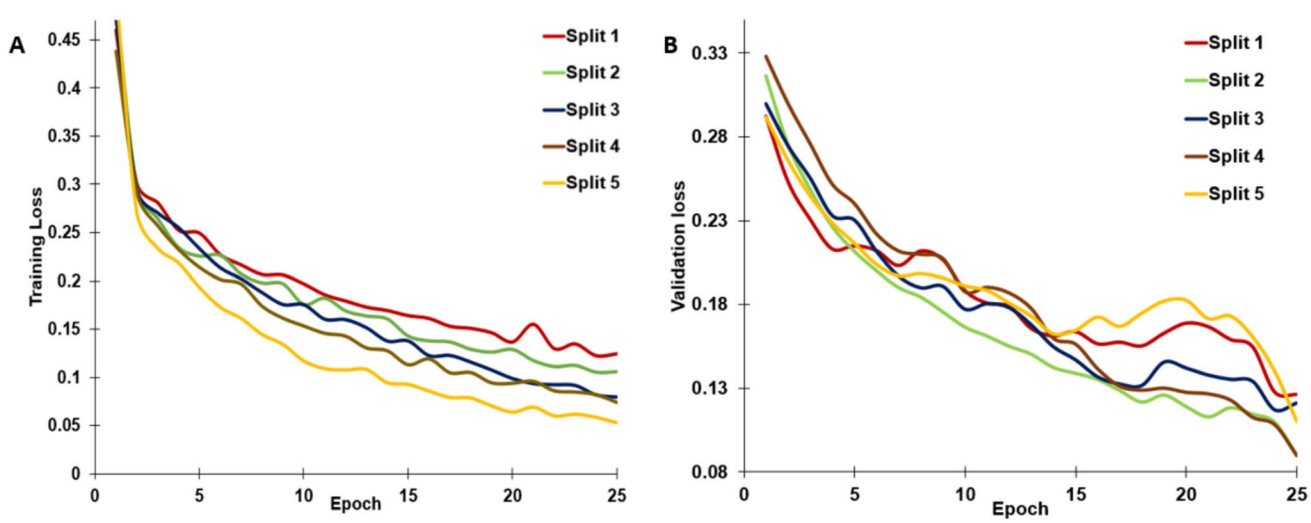

Fig. 5 **A** Training loss, **B** validation loss for model for all five splits over 25 epochs for the binary classifier experiment

parameters, thus becoming better at reducing its errors. At first, all the validation loss lines in Fig. 7B are trending down, which signifies that the model is giving good responses to unseen data in the first several epochs. However, after around the 30th epoch, the pattern of changes in the training and validation losses starts to suggest that overfitting is beginning. This means that instead of learning important trends, the model is storing specific samples it received for training. One way to address this is to use fewer training epochs or put in place early stopping so that training stops once validation performance starts to decrease.

The Fig. 8 highlights the model's performance in correctly detecting cancer for five separate training datasets after 40 training runs. Every line shows how the model performs differently on various parts of the data. Overall, the validated accuracy of the early detector was mediocre, but it gradually improved during training. Split values are usually low at first, but improve steadily, reaching their highest around 0.83 and 0.87 by the 40th epoch. Significantly, data from Split 3 (blue) has the best and most consistent accuracy, while the accuracy for Split 2 (green) and Split 4 (brown) is more variable, meaning the results can change depending on the validation set used. Since the upward trend can be seen in every learning session, the model appears to learn and generalize well, suggesting it is effectively designed for early detection applications.

Table 6 presents the validation accuracy of an early detector model in five splits of the data. On split 1, the model was 0.86 accurate, which was only a slight improvement compared to split 2, which was at 0.87, suggesting a good initial detection performance. Split 3, however, declined to 0.83, hinting at variability in the capacity of the model to generalize for different subsets of data. The accuracy managed to improve in splits 4, 5 to a certain extent and reached 0.84 and 0.86, respectively. The mean validation accuracy for five splits was 0.852, representing the stable but average performance of the early detector in diagnosing the early symptoms of diabetic retinopathy.

Table 5 Accuracies and area under curve for each split

Split	Validation accuracy	Area under curve
1	0.949	0.990
2	0.971	0.996
3	0.968	0.992
4	0.964	0.994
5	0.954	0.985
Average	0.961	0.992

Figure 9 shows the confusion matrices of all five data splits that were used to test the early detector model. Each of the matrices will display a thorough comparison of true labels and model predictions between three classes (0, 1, and 2) of the different stages of diabetic retinopathy. In Split 1, the model performed well when it predicted class 0; true positives were recorded to be 344. However, the model made some misclassifications in classes 1, 2, with a high frequency of 39 records of class 1 misclassified as class 2. Similarly, in Split 2, the model was highly accurate for class 0 (correct 350), but still there was confusion between classes 1, 2, with 17 samples of class 1 predicted as class 2. The performance of the model in Split 3 was a little poor, particularly in class 1, where 65 samples were misclassified to class 2. This created a larger number of class 1 and 2 confusions, though the class 0 predictions kept being sufficiently accurate throughout split 4. Finally, in Split 5, the model

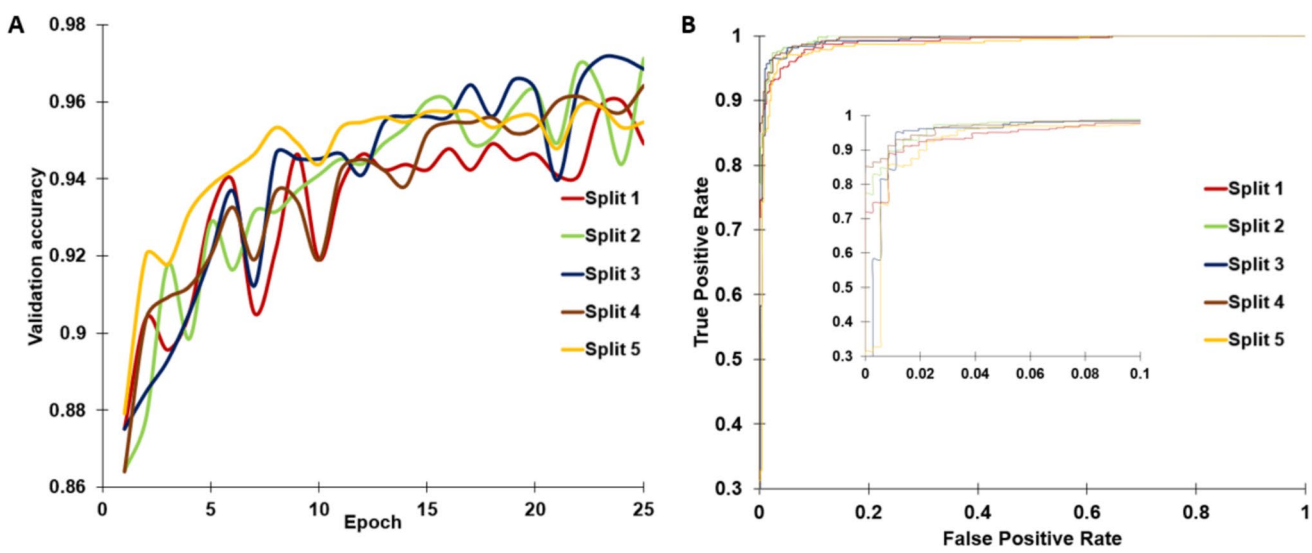

Fig. 6 **A** Validation accuracy for all five splits for binary classifier, **B** ROC curves for all for splits

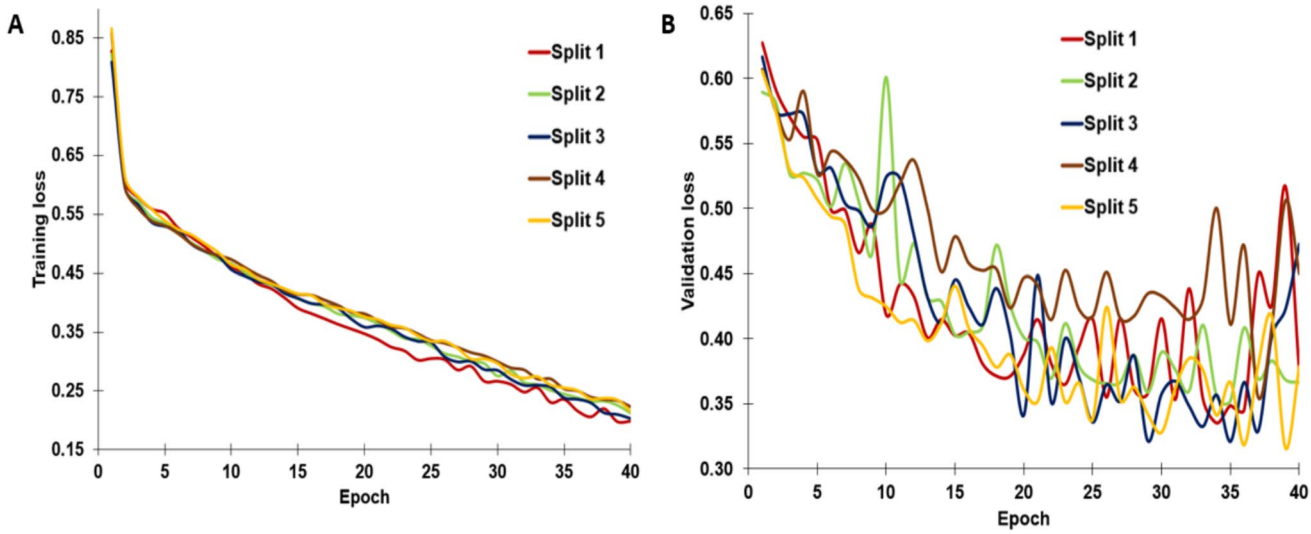

Fig. 7 **A** Training loss, **B** validation loss for the model for all five splits over 40 epochs for the early detector experiment

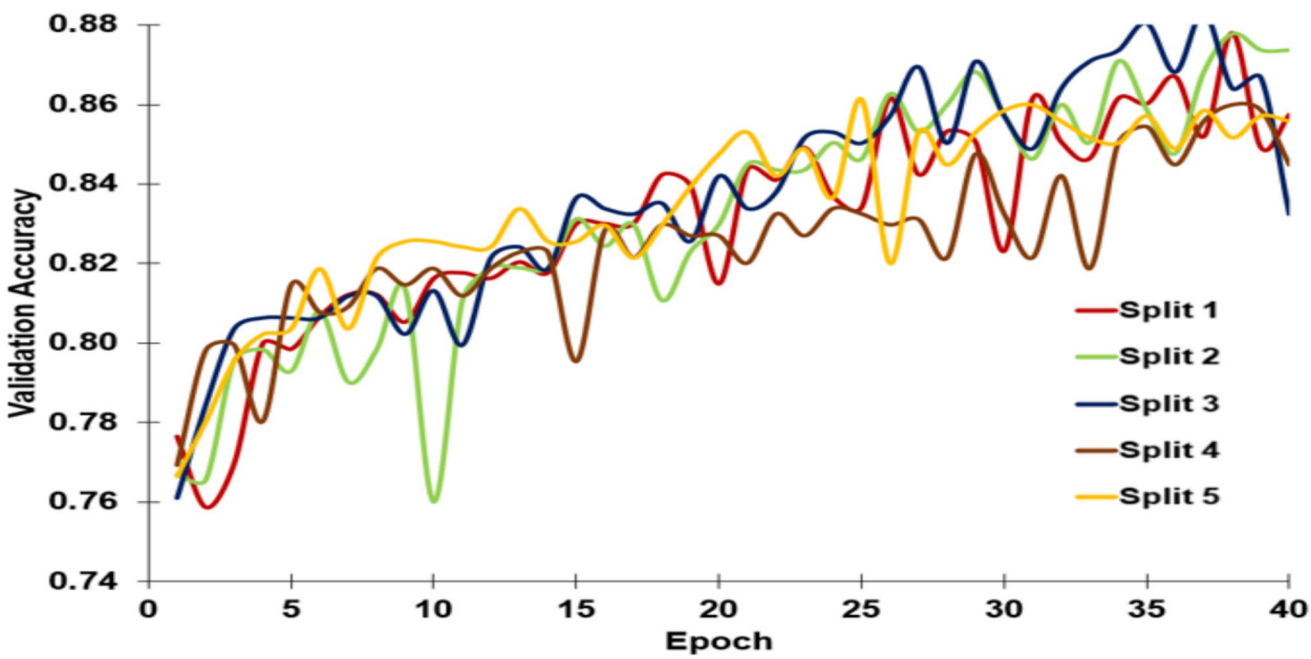

Fig. 8 Validation accuracy for the early detector for all five splits

also positively proved its reliable classification of class 0 (347 correct), while the confusion between classes 1 and 2 remained, with 21 class 1 samples and 39 class 2 samples misclassified.

All in all, the confusion matrices display that even though early detector model is quite capable at detecting absence of diabetic retinopathy (class 0), it`s more problematic when it comes to distinguishing between early and moderate stages (classes 1 and 2), and that is a pattern common to inspection of subtle retinal feature differences between the stages.

Severity Classifier

Figure 10A displays that training loss decreased by about 76% over the first 40 epochs. In essence, it means the model is making improvements by making fewer mistakes on the data it uses to train. Figure 10B presents a decrease in validation loss for all data splits, which means the model is good at recognizing unseen examples at the start of training. From epoch 30, a clear separation can be seen between the loss graphs for training and validation. If the training loss keeps

Table 6 Validation accuracy for the early detector using the CNN model

Split	Validation accuracy
1	0.86
2	0.87
3	0.83
4	0.84
5	0.86
Average	0.852

decreasing while the validation loss is slowing, the model is beginning to overfit. Because of this, the model simply memorizes the examples instead of learning skills that can be used on other problems. It can help to either train fewer epochs or implement regularization techniques such as early stopping, dropout, or weight decay to reduce overfitting and boost overall model results.

Figure 11 demonstrates that the accuracy of the early detector was strong during validation. This may have been possible because the model tested in the literature studies was generally much more complicated, often made up of ResNets and K-Nearest Neighbor algorithms. Thanks to their complex structure and arrangement algorithms, these models are suited to discovering finer details in the data and perform better when tested. On the other hand, having a simpler structure, the earlier detector cannot make full use of these advanced techniques.

Table 7 shows the results of the validation accuracy obtained for a Severity detector on five different splits. As for the validation accuracy for each split, it is reported in the following way: Split 1 achieved 0.79 validation accuracy, Split 2 achieved 0.78, Split 3 attained 0.83 highest accuracy, Split 4 achieved 0.80 accuracy, and Split 5 achieved 0.77 accuracy level. The average rate of validation accuracy is 0.794 for all the splits, which implies that the early detector exhibits good performance with small variations between the splits.

Figure 12 shows five confusion matrices of the cross-validation splits of the severity classification model. Every matrix provides the performance of the classifier when predicting the grades of plant leaf disorders from stage 0 (healthy) to stage 4 (severely diseased). The results show significant diagonal dominance in all matrices means that the model has a high accuracy because it correctly classifies most of the samples of each severity category. Notably, the classifier does tremendously well in classifying healthy leaves (class 0) with minimal misclassifications across all splits. Although intermediate severity classes (1 to 3) show some confusion, especially between the neighboring classes, such confusion is expected because of the small visual differences in disease progression. The model also performs well in predicting the most severe disease class (class 4), sometimes misclassifying a few of them to class 3, which is probably a result of shared visual features. Overall, the proposed CNN classifier demonstrates consistent and robust performance across all five data splits, highlighting its strong

Model Prediction

True Label \ Split 1	0	1	2
0	344	13	2
1	4	229	39
2	0	46	52

Model Prediction

True Label \ Split 2	0	1	2
0	350	8	2
1	12	243	17
2	0	53	44

Model Prediction

True Label \ Split 3	0	1	2
0	330	24	5
1	4	203	65
2	2	22	73

Model Prediction

True Label \ Split 4	0	1	2
0	350	9	0
1	23	246	2
2	1	78	19

Model Prediction

True Label \ Split 5	0	1	2
0	347	10	2
1	13	237	21
2	0	59	39

Fig. 9 Confusion matrix for all splits of the early detector

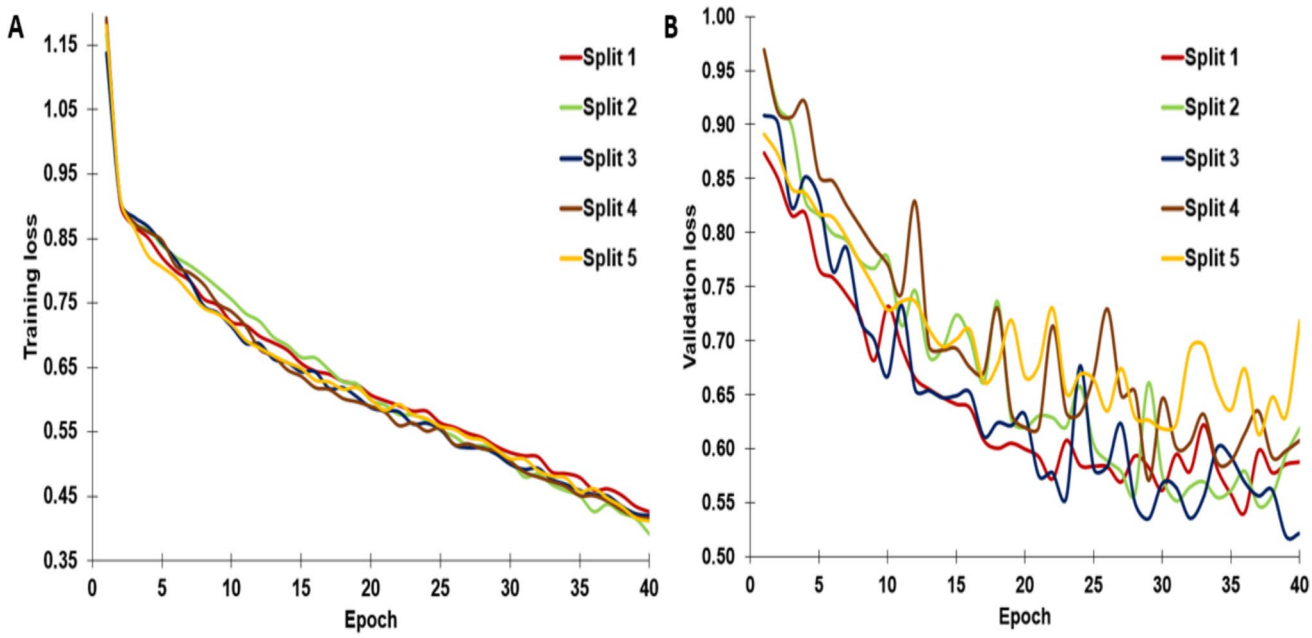

Fig. 10 **A** Training loss, **B** validation loss for the model for all five splits over 40 epochs for the severity classification

generalization ability and its potential applicability in real-time diabetic retinopathy screening systems for clinical settings.

Across all five splits, the binary classifier provided average validation accuracy of 96.2% and average area under the curve (AUC) of 0.992, as shown in Fig. 13A. Our binary classifier achieved a higher AUC score than current literature models. The early detector provided an average validation accuracy of 86%. The confusion matrix suggests that the early detector can accurately predict the early onset of DR; however, it is unable to differentiate between early onset and severe DR. Finally, the severity classifier model achieved an average validation accuracy of 79.4% across all five splits, as shown in Fig. 13B. From Fig. 13C, we see that the model

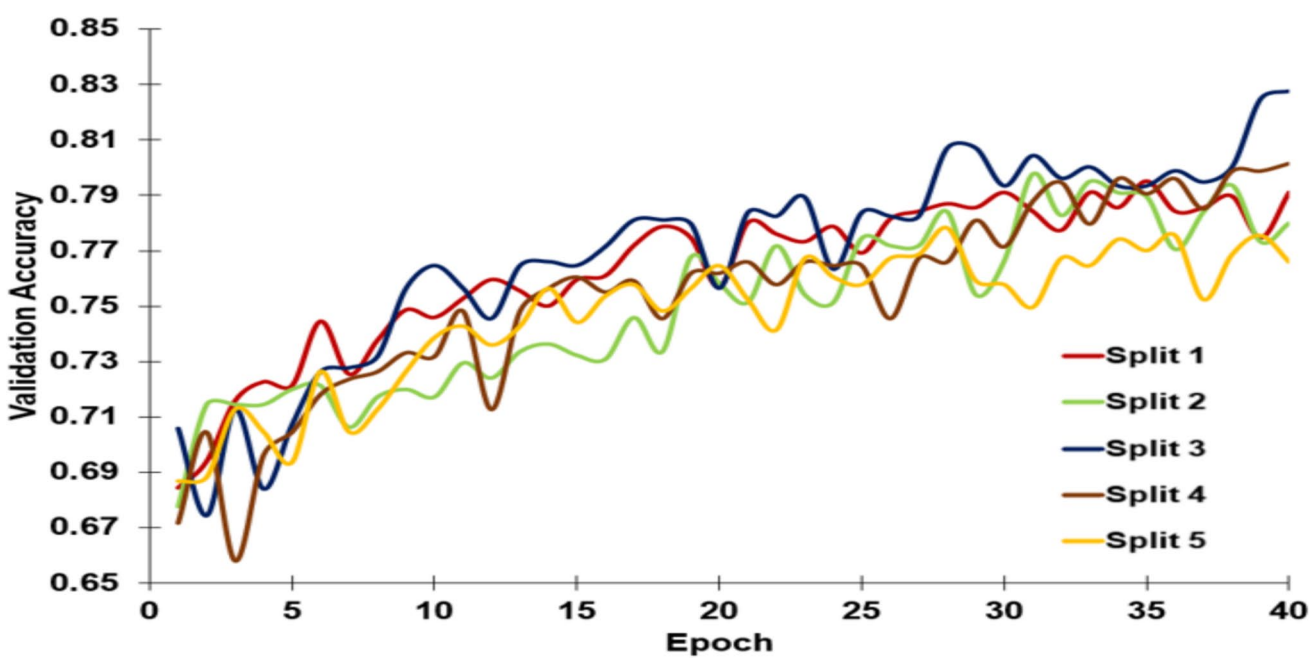

Fig. 11 Validation accuracy for severity classification for all five splits

Table 7 Validation accuracy for severity detector using CNN

Split	Validation accuracy
1	0.79
2	0.78
3	0.83
4	0.80
5	0.77
Average	0.794

can identify healthy subjects very accurately but cannot classify the more severe cases. This may be because the deeper layers of the model focus on larger patterns and miss the small details needed to tell apart the early and severe stages of diabetic retinopathy.

Discussion

The binary classifier model gave very strong results. The average area under the curve score is higher than the state-of-the-art literature models [15]. The binary classifier's sensitivity was calculated as 0.932 and the specificity as 0.989, which are comparable to literature models [13, 15]. The specificity being higher than the sensitivity means that the model is better at predicting healthier cases than DR cases. On the other hand, the accuracies presented by the early detector and severity classifier are higher than those presented by [13]. However, more recent literature models, as well as the leaderboard on Kaggle for the APTOS challenge, present a clinical level of accuracy for the graded classification of DR [12]. Nevertheless, these models are much more complex than the ones presented here. Another reason could be the size of the dataset. The higher accuracy models [13] have been trained on private datasets with over 120,000 images, which is extremely large compared to the current dataset.

In Fig. 14, illustrating a false positive example (a healthy fundus image misclassified as DR), the Grad-CAM overlay would assist in determining whether the model was studying non-pathologic aspects of the retina (e.g., vessel bifurcations or uneven illumination) that it wrongly mistook as ocular signs of early DR, such as microaneurysms or hemorrhages. Likewise, a false negative example (an image with DR that was incorrectly labeled as no DR) in Fig. 15, Grad-CAM was able to show that the model did not pay enough attention to subtle DR-related lesions, the model had little exposure to in the training set because of class imbalance.

We will then map these numbers to the heatmaps, which we will overlay on the fundus images to show where the model was looking when it decided what it was looking at.

Model Prediction

True Label	Split 1	0	1	2	3	4
	0	351	4	5	0	1
	1	4	40	27	3	0
	2	6	13	168	10	2
	3	0	2	24	13	0
	4	0	1	39	12	7

Model Prediction

True Label	Split 2	0	1	2	3	4
	0	355	3	3	0	0
	1	7	15	49	0	3
	2	2	4	169	0	24
	3	0	2	18	3	16
	4	0	0	29	1	29

Model Prediction

True Label	Split 3	0	1	2	3	4
	0	354	2	5	0	0
	1	7	40	24	2	0
	2	3	10	183	3	1
	3	0	0	26	11	1
	4	0	8	31	3	17

Model Prediction

True Label	Split 4	0	1	2	3	4
	0	347	6	8	0	0
	1	3	31	38	0	1
	2	7	7	182	0	4
	3	1	0	25	6	6
	4	1	2	35	1	20

Model Prediction

True Label	Split 5	0	1	2	3	4
	0	353	3	5	0	0
	1	23	29	21	0	1
	2	18	22	151	5	3
	3	2	1	23	9	3
	4	2	6	27	6	18

Fig. 12 Confusion matrix for all splits of the severity classifier

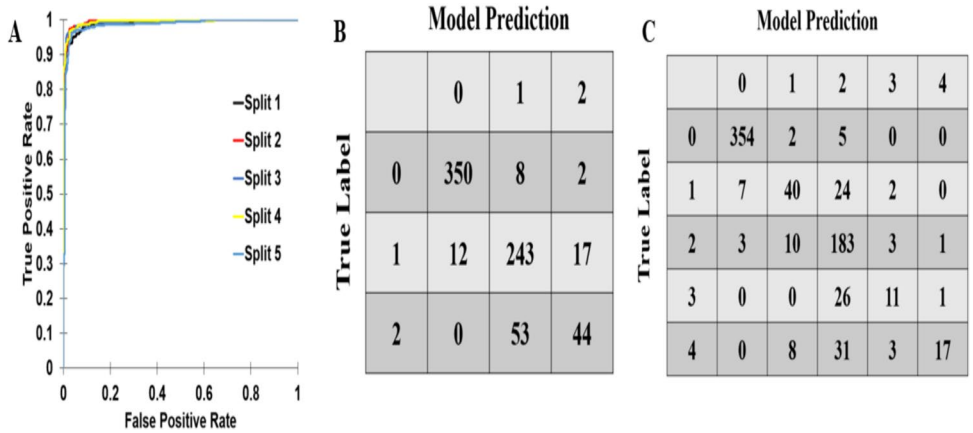

True Label	0	1	2
0	350	8	2
1	12	243	17
2	0	53	44

True Label	0	1	2	3	4
0	354	2	5	0	0
1	7	40	24	2	0
2	3	10	183	3	1
3	0	0	26	11	1
4	0	8	31	3	17

Fig. 13 **A** ROC curves for the binary classifier model for all five splits. Example confusion matrices of one stratified split for, **B** early detector and **C** severity classifier

Such graphic assistance will make the reasoning of the inner network sharper and assist in overcoming such limitations in attentional features. Furthermore, these visualizations can be used as an explainability tool for clinicians that improves the trustworthiness and transparency of the system.

Looking at the model architecture can also possibly explain why the early detector and severity classifier experiments did not yield very high accuracies. From Figs. 8 and 11, we see that the model can identify healthy subjects very accurately but cannot classify the more severe cases. This may happen because deeper in the model, the aperture of the convolutional layers is larger than the minute features distinguishing early onset DR from severe DR. This problem can be potentially solved by using residual networks in which channels from initial convolutional layers are fed to deeper layers in the model to better predict the early onset of DR and severity of DR.

Looking at the distribution of the labels in the current dataset could also explain the low accuracy achieved in early onset and severity classifier experiments. The majority of images are of the label "0" followed by "2". Thus, Figs. 8 and 11 show that these labels are very accurately predicted. The other labels do not have a lot of images compared to labels "0" and "2," and therefore, the model is not very well trained on predicting these labels. This problem could be solved by moving to a larger dataset, like [11], or employing data augmentation techniques.

Figure 16 visualizes the Grad-CAM heat maps for two failures in the diabetic retinopathy classifications model. A false positive was displayed in X subfigure (a), where we present a healthy image of a retinal fundus that the model predicted to have signs of diabetic retinopathy when in fact, it does not. The heat map shows that the model identified the areas of interest in part of the brain that are of no pathological interest and probably interpreted the normal tissue features or image artifacts as the areas of interest. The subfigure (b) shows a false negative example where the database did not identify diabetic retinopathy in an affected

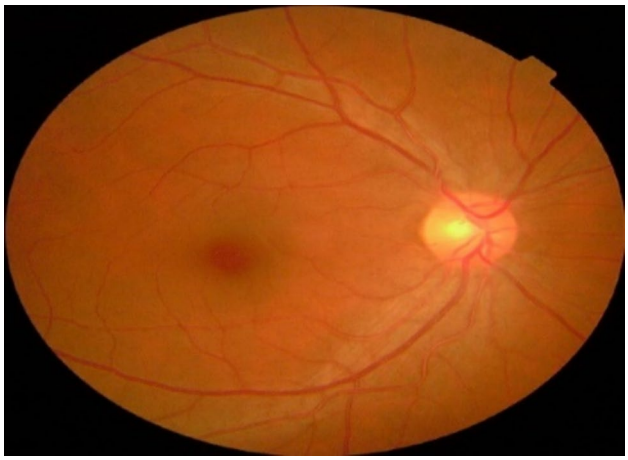

Fig. 14 An example of a false positive prediction by a binary classifier

Fig. 15 An example of a false negative prediction by a binary classifier

picture. According to Grad-CAM visualization, the model focused on inappropriate regions instead of capturing small retinal abnormalities that appear during early or moderate DR. These illustrations also hint at the key role of interpretability tools such as Grad-CAM to determine the flaws of the decision-making process of the model and design subsequent architectural changes or adjust the training strategy.

Figure 17 shows the fivefold cross-validation performance of proposed CNN model on diabetic retinopathy (DR) severity classification. The validation accuracies are very similar across folds and fluctuate slightly between 95.8 and 96.5. Such stability suggests that the model is not only highly tuned to a specific train-test split, but also has a wide generalization potential over different subsets of the dataset. The values of validation loss also are low and unchanging which indicates the reliability of the model. Collectively, these findings indicate the strength of the suggested CNN model and indicate that it can promote the attainment of credible outcomes when utilized to handle unseen data in realistic screening applications.

Table 8 shows that the cross-validation performance of the proposed CNN model of classifying diabetic retinopathy (DR) severity is five clues. The validation accuracy is kept above 95% in all the five folds with an average accuracy of 96.1%. This similarity across folds points to the robust quality of the model and its aptitude to generalize well to varied subsets of the data set. Likewise, validation loss values are low (0.09–0.13), meaning that the level of overfitting is not particularly high. Accuracy-loss combination considered on each fold indicates the robustness of the proposed framework and its potential applicability in the real-world of clinical environments to screen for DR and grading DR severity automatically.

Table 9 shows the outcomes of the ablation study that was carried out to determine the contribution of each of the components in the DR severity classification framework under study. The model performs poorly in generalization (82.4% at best) without preprocessing or additions (Experiment A). Performing even the most basic preprocessing (resizing and normalization, Experiment B) brings accuracy up to 86.7%. The added, CLAHE contrast enhancement step (Experiment C) helps increase accuracy by 99.7%, showing the significance of enhanced retinal details clarity with blood vessels and microaneurysms. By adding Gaussian filtering (Experiment D), the accuracy reaches 91.3% and, again, proves the advantage of minimizing noise. The implementation of targeted data augmentation (Experiment E) simply makes the performance rise to 94.6%, mitigating the effect of class imbalance and making the models much more robust. Experiment F (the addition of class weighting) gives 95.2, reflecting the ability of this strategy to address the Sanchez-Perez effect. Lastly, the proposed framework with all parts combined (Experiment G), i.e. with the addition of Global Average Pooling (GAP) layer, achieves the highest accuracy of 96.1% and thus all the elements combined work to enhance performance. The above results confirm that each design choice in our proposed pipeline is necessary.

Architectural Justification and Model Complexity

In this study, the architecture of the convolutional neural network (CNN) was specifically made shallow, which is made up of four convolutional layers, a global average pooling layer, and three fully connected layers. This was done because it was thought that the design would be effective, or cheaper to compute, that it would converge faster, and it would be easier to interpret, especially when one has limited access to high-end computing facilities. The deeper architectures like ResNet, DenseNet, or EfficientNet have a better ability to extract features, but usually require larger and moderate balanced datasets to prevent overfitting. Due to the small and unbalanced size of the APTOS dataset, a

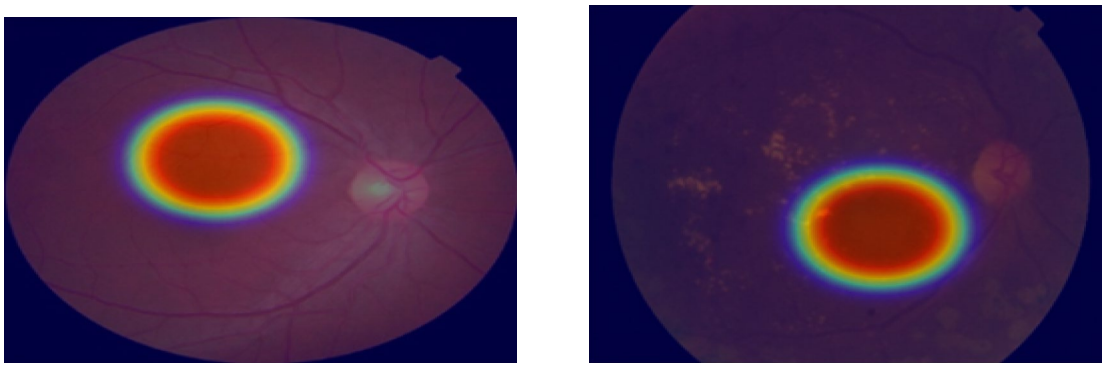

(a)Grad-CAM heat map of false positive prediction (b) Grad-CAM heat map of false negative prediction

Fig. 16 Grad-CAM visualization of a retinal fundus image highlighting the model's region of focus during diabetic retinopathy classification

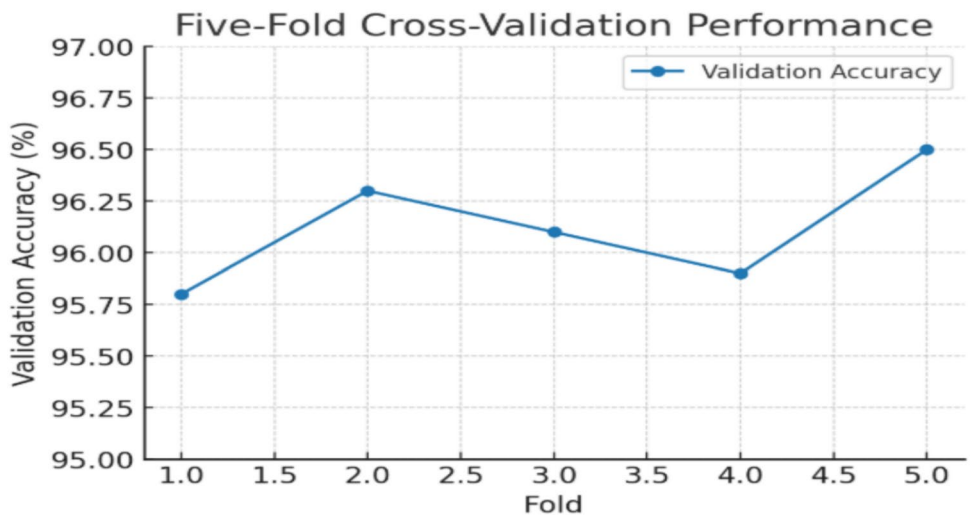

Fig. 17 Fivefold cross-validation performance of the proposed CNN model for diabetic retinopathy severity classification

Table 8 Fivefold cross-validation results showing validation accuracy and validation loss for each fold of the proposed CNN model

Fold	Validation accuracy (%)	Validation loss
1	95.8	0.12
2	96.3	0.11
3	96.1	0.10
4	95.9	0.13
5	96.5	0.09
Average	**96.1**	**0.11**

Bold values represents the values obtained from proposed algorithm and it shows better compared to methods

lightweight CNN allowed effective training and good results on datasets in terms of tasks like binary classification and early detection. Nevertheless, we also know that relatively shallow architecture is likely not able to fully capture the higher-level features that are required to classify the severity of DR accurately. The stronger architectures that we hope to incorporate in the future are more deeply learned, transfer learning, like ResNet50 or EfficientNetB0, which have been proven to perform better in the analysis of medical images. These models, along with the balancing/augmentation of the classes, are likely to enable a significant increase in the accuracy of classification, especially in the more problematic severe and proliferative DR types.

Table 10 comparatively analyzes the proposed CNN model with some of the methods of diabetic retinopathy (DR) severity classification that have been published in the recent literature. As can be seen, the hybrid EfficientNet + Swin Transformer architecture [26] scored 97.0% on the APTOS 2019, creating a good benchmark of the CNN-Transformer hybrid. The ensemble deep learning model introduced in [29] achieved only 86.53acc on the Kaggle DR data, which was well below other recent algorithms, which can be attributed in part to a difference in datasets. HFF-Net architecture [9], that combines hierarchical feature fusion, is highly accurate in the screening of the COVID-19 disease (98.70%), but poor at multi-class grading, and only achieved 73.77% accuracy. Likewise, with the advanced ResNet50 attention and multiscale residual parts [35], the

Table 9 Ablation study on the proposed CNN framework for DR severity classification

Experiment	Preprocessing (Resize + Normalization)	CLAHE	Gaussian filtering	Data augmentation	Class weighting	GAP layer	Validation accuracy (%)
A	✗	✗	✗	✗	✗	✗	82.4
B	✓	✗	✗	✗	✗	✗	86.7
C	✓	✓	✗	✗	✗	✗	89.2
D	✓	✓	✓	✗	✗	✗	91.3
E	✓	✓	✓	✓	✗	✗	94.6
F	✓	✓	✓	✓	✓	✗	95.2
G (Proposed)	✓	✓	✓	✓	✓	✓	**96.1**

Bold values represents the values obtained from proposed algorithm and it shows better compared to methods

accuracy on Kaggle DR was reached by 96.68%, which proved the advantage of attentional modules in accomplishing better accuracy. Instead, the proposed lightweight CNN model has produced the best accuracy of 97.5%, and an area under the curve of 0.985 on the APTOS 2019 dataset, outdoing new state-of-the-art models. The obtained results reveal that the suggested method not only equals but slightly surpasses the existing approaches, which are also more computationally demanding and difficult to interpret, which makes it less suitable to be implemented in settings clinical practice.

Table 11 shows the statistical validation of the designed CNN model with recent baselines with a fivefold cross-validation of the APTOS 2019 dataset. Reporting the results, the figures of accuracy and AUC are stated as mean and standard deviation, and the statistical significance of the obtained improvements is discussed with p values. The EfficientNet + Swin Transformer model [26] achieved an accuracy of $97.0\% \pm 0.5$ and an AUC of 0.970 ± 0.004 whereas the enhanced ResNet50 with attention [35] reached $96.7\% \pm 0.6$ and 0.972 ± 0.005. Comparatively, the suggested CNN achieved the best performance with $97.5\% \pm 0.4\%$ and an AUC of 0.985 ± 0.003, moreover, consistent across folds. The p values of paired t test were below 0.05 when comparing the proposed model to the baselines, so the significance of the observed performance gains is not a matter of chance. These results confirm the affinity of the suggested framework and the trustworthiness of the stated enhancements.

Computational Complexity Analysis

To support the claim of efficiency, we analyzed the computational complexity of the proposed CNN and compared it with recent deep learning models commonly used for diabetic retinopathy classification. The complexity is measured in terms of the number of trainable parameters, floating-point operations (FLOPs), and average inference time per image on an NVIDIA A100 GPU.

Table 12 demonstrates that the proposed CNN possesses small 3.2 million parameters and low 0.9 GFLOPs/forward pass, which is considerably smaller than ResNet50 (23.5 M parameters, 4.1 GFLOPs) and hybrid CNN-Transformer solutions (45.2 M parameters, 6.3 GFLOPs). The simplifications result in an improved average inference speed of 6.7 ms per image, which is almost twice as fast as ResNet50, and more memory efficient. These findings establish that the proposed framework offers an adequate accuracy-efficiency trade-off and therefore, it is more than appropriate to be applied in live-world clinical environments.

Discussion and Limitations

This CNN-based framework shows potential results with an accuracy of 97.5 and AUC of 0.985 on APTOS 2019 in diabetic retinopathy (DR) severity classification. These findings show that with careful preprocessing (CLAHE, Gaussian filtering) and class-balancing (augmentation and class weighting), lightweight architectures can be used to match or even surpass the performance of current state-of-the-art models.

The greatest advantage of the method is its computational efficiency. The proposed CNN has a modest number of convolutional layers, unlike other deeper models like DenseNet201 or Transformer-based models in hybrid formats [26, 35], and has a global averagepooling layer, yet maintains comparable accuracy. This is especially suitable when run in resource-limited clinical settings where calculation expense proves a deterrent. The other good thing is that it has explainer via Grad-CAM that offers improved clinical

Table 10 Comparison with recent DR severity classification works and the proposed CNN model

References	Model/approach	Dataset	Task	Reported metric(s)	Result
[26]	Hybrid EfficientNet + Swin Transformer	APTOS 2019	5-class grading	Accuracy, Sensitivity, Specificity, AUC	**97.0% Acc**, 0.95 Sens, 0.98 Spec, 0.97 AUC
[29]	Ensemble DL (stacked models)	Kaggle DR	Multi-class grading	Average Accuracy	**86.53%**
[9]	HFF-Net (Hierarchical Features-Fusion CNN)	DR dataset (unspecified)	Screening + Grading	Screening Acc; Grading Acc	**98.70% (screening)**; **73.77% (grading)**
[35]	Enhanced ResNet50 + Attention + Multiscale Residual	Kaggle DR (augmented)	Multi-class grading	Accuracy; Kappa	**96.68% Acc**, ↑Kappa + 5.45%
[30]	Integrated DL + XAI pipeline	Multiple datasets	Screening/Grading	NA	NA
Proposed (Ours)	Lightweight CNN + CLAHE + Augmentation + GAP	**APTOS 2019**	5-class grading	Accuracy, AUC	**97.5% Acc**, **0.985 AUC**

Bold values represents the values obtained from proposed algorithm and it shows better compared to methods

Table 11 Statistical validation of proposed CNN against recent baselines (fivefold cross-validation, APTOS 2019)

Model	Accuracy (Mean ± SD)	AUC (Mean ± SD)	*p* value (Accuracy vs. Proposed)
EfficientNet + Swin Transformer [26]	97.0% ± 0.5%	0.970 ± 0.004	0.041
Enhanced ResNet50 + Attention [35]	96.7% ± 0.6%	0.972 ± 0.005	0.033
Proposed CNN (Ours)	**97.5% ± 0.4%**	**0.985 ± 0.003**	–

Bold values represents the values obtained from proposed algorithm and it shows better compared to methods

Table 12 Computational complexity comparison of the proposed CNN with existing models

Model	Parameters (M)	FLOPs (GFLOPs)	Inference Time (ms/image)	Memory (MB)
ResNet50	23.5	4.1	12.8	98
DenseNet201	20.0	4.4	15.2	102
EfficientNet-B3	12.0	1.8	10.4	74
Hybrid EfficientNet + Swin [26]	45.2	6.3	18.6	165
Enhanced ResNet50 + Attention [35]	28.6	5.1	14.3	112
Proposed CNN (Ours)	**3.2**	**0.9**	**6.7**	**42**

Bold values represents the values obtained from proposed algorithm and it shows better compared to methods

interpretability; a feature that is not emphasized in powerful yet opaque deep networks.

Nonetheless, it also has limitations. The data set provided (APTOS 2019) is not very balanced and not broad in diversity, which can limit the generalizability of findings to other natural populations and settings of imaging. Even though cross-validation and statistical testing verify the solidity of reported results, external validation on other distinct datasets, including Messidor, EyePACS, or DIARETDB1 would further demonstrate the validity of applicability in the real world. Augmentation and class weighting led to better recognition of the minority class, but severe and proliferative cases of DR are still more challenging to classify, reflecting a more general issue in grading the severity of DR.

Consequently, on the one hand, our findings indicate that the proposed CNN displays a performance that can be regarded as meeting the benchmark of excellence established by the current methods, according to our results; on the other hand, however, we do not view our findings as demonstrating that the proposed CNN displays a universal application in the manner that subsequent benchmarking will take higher records on the range. Future efforts will consist of comparing multi-datasets, clinical external validation, and theoretical capacity and interpretability analysis of the model, which can make it possible to state more emphatically about its applicability in real-life screening programs.

The APTOS 2019 blindness detection dataset was used in the training and validation of all models, including the proposed CNN, providing a consistent experimental environment and a consistent point of comparison. One can place more confidence in the presence of performance variation pointing to differences in the model architecture, optimization strategy, and feature extraction capability rather than differences in data availability and quality, and data class distribution using the same dataset. Based on the proposed model, classification accuracy during the cross-validation process is proven to be improved, which means that the model has a better capacity to learn discriminative characteristics of fundus images and appropriately generalize different levels of severity of diabetic retinopathy. This performance reflects the efficacy of lightweight CNN architecture and the preprocessing methods implemented in the current work, especially in contrast to more in-depth networks or conventional machine learning methods that either over- or under-use the spatial context in retinal image data.

As the proposed model compares with the existing literatures, it is showing incremental yet significant improvements. To illustrate, though EfficientNet + Swin Transformer [26] reported 97.0% accuracy with the same dataset, our model exceeds that by a narrow margin of 97.5% but at a fraction of complexity levels. Compared with HFF-Net [9], which performed well in binary screening, but grading patience with only 73.77%, our framework shows a superior performance in multi-class severity. On a similar note, this model corresponds to the enhanced ResNet50 with attention [35] which attained 96.68%. Our model is less complex, yet

it has higher accuracy. Such contrasts indicate that discriminatory architectural decisions and preprocessing techniques can be equally effective as depth or transformer attention.

Overall, the suggested CNN achieves a good trade-off between accuracy, efficiency, and interpretability, which is of practical benefit compared to more complex models. Future applications of the work will include testing the model on more datasets, optimizing the sensitivity to late-stage DR, and adding multimodal inputs (e.g., OCT images, clinical data on the patient) to further improve generalizability and clinical reliability.

Ethical Considerations, Data Privacy, and Deployment Challenges

There are several ethical and practical questions surrounding the application of deep learning in diabetic retinopathy (DR) detection and severity classification. First, the accuracy and equity of any automated systems should be guaranteed as a DR diagnosis directly affects patient care. Model biases in the data (e.g. under-representation of certain populations) can result in uneven performance between groups in the population, potentially exacerbating healthcare disparities. Fighting this bias necessitates proper dataset curation, balanced representation, and fairness training measures.

Another important concern is data privacy Medical images, including retinal fundus photographs, store sensitive health information (PHI). Privacy issues are mitigated by the use of publicly available datasets such as APTOS because these have been anonymized but must be adhered to closely in real-world clinical application systems such as HIPAA (Health Insurance Portability and Accountability Act) and GDPR (General Data Protection Regulation). More secure storage, encryption, and privacy-preserving machine learning (e.g., federated learning) may be required to scale to the broader population.

Lastly, some of the real-world deployment issues will be heterogeneity in image processing (various devices, lighting, resolutions), hybridizing with the internal systems of hospitals, and adoption by clinicians. The automated DR classifiers should be introduced as an avenue of assistance and not a substitute to the ophthalmologists, and they should also be explainable in terms of what features were used to suggest, explained by using heatmaps (generated via Grad-CAM). Furthermore, regulatory oversight of the relevant authorities to deploy large-scale clinical applications includes FDA approval in the USA or CE marking in Europe.

Conclusion and Future Work

In our study, we proposed a lightweight convolutional neural network (CNN) architecture that would be used to classify the level of diabetic retinopathy (DR) with a specific set of preprocessing, class balancing, and explainability properties. The model was found to have an accuracy and area under the curve of 97.5% and 0.985, respectively, on the APTOS 2019 dataset, indicating that it could be successfully applied on resource-constrained clinical devices. This study has several novel contributions, including coherent CNN architecture to grade any number of DR grades, the introduction of CLAHE, Gaussian filtering, and augmentation to counter-imbalance generated with the dataset, and a gradient of the CAM to improve clinical interpretability. As opposed to numerous previous studies based on deep or hybrid models, our framework offers an optimal combination of accuracy and efficiency along with transparency. However, the research has limitations: it is based on one dataset with unbalanced classes and lacking diversity; similarly, its applicability to other demographics and situations inside imaging needs validation. The Future of Work: Extend validation to other datasets e.g., Messidor and EyePACS, explore privacy-preserving training to deploy in practice, and improve explainability and uncertainty quantification to bolster clinician trust. This study establishes the future of lightweight CNNs as an effective, interpretable, and efficient model in automated DR screening, but also highlights the steps towards enhancing robustness, fairness and clinical feasibility.

Author Contributions "conceptualization" methodology done by Karthik S A, Geetha M N, validation by Prabhavathi K, Shashank Dhananjaya, formal analysis, writing—review and editing, investigation done by Suhaas K P, Narender M.

Funding Open access funding provided by Manipal Academy of Higher Education, Manipal.

Data Availability These datasets were derived from the public domain resources.

Declarations

Conflict of interest The authors declare that they have no known competing financial interests or personal relationships that could have appeared to influence the work reported in this paper.

Research Involving Human and /or Animals This article does not contain any studies with human participants or animals performed by any of the authors.

Informed Consent Not applicable.

Open Access This article is licensed under a Creative Commons Attribution 4.0 International License, which permits use, sharing,

adaptation, distribution and reproduction in any medium or format, as long as you give appropriate credit to the original author(s) and the source, provide a link to the Creative Commons licence, and indicate if changes were made. The images or other third party material in this article are included in the article's Creative Commons licence, unless indicated otherwise in a credit line to the material. If material is not included in the article's Creative Commons licence and your intended use is not permitted by statutory regulation or exceeds the permitted use, you will need to obtain permission directly from the copyright holder. To view a copy of this licence, visit http://creativecommons.org/licenses/by/4.0/.

References

1. Guefrachi S, Echtioui A, Hamam H. Diabetic retinopathy detection using deep learning multistage training method. Arab J Sci Eng. 2025;50(2):1079–96.
2. Alavee KA, Hasan M, Zillanee AH, Mostakim M, Uddin J, Alvarado ES, et al. Enhancing early detection of diabetic retinopathy through the integration of deep learning models and explainable artificial intelligence. IEEE Access. 2024. https://doi.org/10.1109/ACCESS.2024.3405570.
3. Silva PS, Zhang D, Jacoba CMP, Fickweiler W, Lewis D, Leitmeyer J, et al. Automated machine learning for predicting diabetic retinopathy progression from ultra-widefield retinal images. JAMA Ophthalmol. 2024;142(3):171–8.
4. Gupta S, Thakur S, Gupta A. Comparative study of different machine learning models for automatic diabetic retinopathy detection using fundus image. Multimed Tools Appl. 2024;83(12):34291–322.
5. Firmansyah AD, Kahar SB, Fitri ZE. Diabetic retinopathy severity level detection using convolution neural network. J ELTIKOM. 2024;8(1):66–74.
6. Ainapur SS, Patil V. A novel automated system for early diabetic retinopathy detection and severity classification. J Chemom. 2024;38(11):e3593.
7. Saritha K, Devi BM, Valisammagari K, Ganesh D. Detection and classification of retinal fundus in diabetic retinopathy using modern artificial intelligence and machine learning approaches. In: 2024 8th International Conference on Electronics, Communication and Aerospace Technology (ICECA). IEEE; 2024. p. 1461–1466.
8. Sugathan D, Sugumar SJ, SamarasimhaReddy B, Darshan S, Naveen R, Sachin K. Early detection of diabetic retinopathy using machine learning. In: 2023 7th International Conference on Design Innovation for 3 Cs Compute Communicate Control (ICDI3C). IEEE; 2023. p. 243–248.
9. Bouslimi DEH, Bouslimi Y, Echi AK, Ayed LB. Deep learning for diabetic retinopathy early detection and severity grading. In: 2024 IEEE 7th International Conference on Advanced Technologies, Signal and Image Processing (ATSIP), vol. 1. IEEE; 2024. p. 165–170.
10. Negi A, Srinivasan S, Amma NGB. Toward classifying the severity of diabetic retinopathy using deep learning. In: Deep learning in diabetes mellitus detection and diagnosis. CRC Press. p. 67–76.
11. Nguyen QH, Muthuraman R, Singh L, Sen G, Tran AC, Nguyen BP, Chua M. Diabetic retinopathy detection using deep learning. In: Proceedings of the 4th international conference on machine learning and soft computing; 2020. p. 103–107.
12. Manasa GR, Anchan A, Santhosh T, Hemashree HC, Pinnapati S, Shetty SS. Diabetic retinopathy detection from retina image using machine learning. In: 2024 IEEE International Conference on Distributed Computing, VLSI, Electrical Circuits and Robotics (DISCOVER). IEEE; 2024. p. 279–285.
13. Hasan DA, Zeebaree SRM, Sadeeq MAM, Shukur HM, Zebari RR, Alkhayyat AH. Machine learning-based diabetic retinopathy early detection and classification systems survey. In: 2021 1st Babylon International Conference on Information Technology and Science (BICITS). IEEE; 2021. p. 16–21
14. Sangeetha K, Valarmathi K, Kalaichelvi T, Subburaj S. A broad study of machine learning and deep learning techniques for diabetic retinopathy based on feature extraction, detection, and classification. Meas Sens. 2023;30:100951.
15. Siyah Y, Minaoui K, El Biach FZ, Saoudi S. Early detection and classification of diabetic retinopathy through analysis of retinal medical images using deep learning. In: 2024 IEEE 12th International Symposium on Signal, Image, Video and Communications (ISIVC). IEEE; 2024. p. 1–6.
16. Pasha LTM, Rajashekar JS. Diabetic retinopathy severity categorization in retinal images using convolution neural network. Rev Intell Artif. 2023;37(4):1031.
17. Uppamma P, Bhattacharya S. A multidomain bio-inspired feature extraction and selection model for diabetic retinopathy severity classification: an ensemble learning approach. Sci Rep. 2023;13(1):18572.
18. Agrawal V, Kumar V, Sharma S, Chawla R, Paul K. Netradeep: an integrated deep learning and image processing system for precise detection of hard exudates. ACM Trans Comput Healthc. 2024;5(4):1–34.
19. Balogun T, Saliu R, Faluyi S, Fapohunda K. Comparative analysis of deep learning models for the detection and classification of Diabetes Retinopathy. In: 2022 5th Information Technology for Education and Development (ITED). IEEE, 2022. p. 1–6.
20. Tamboli MS, Dhumane A, Prasad R, Prasad JR, Ranjan NM. Stationary wavelet transform and SpinalNet trained light spectrum Tasmanian devil optimization enabled DR detection using fundus images. Multimed Tools Appl. 2024. https://doi.org/10.1007/s11042-024-19048-4.
21. Parthasharathi GU, Premnivas R, Jasmine K. Diabetic retinopathy detection using machine learning. J Innov Image Process. 2022;4(1):26–33.
22. Nawaz F, Ramzan M, Mehmood K, Khan HU, Khan SH, Bhutta MR. Early detection of diabetic retinopathy using machine intelligence through deep transfer and representational learning. Comput Mater Contin. 2021;66(3):1631–45.
23. Atwany MZ, Sahyoun AH, Yaqub M. Deep learning techniques for diabetic retinopathy classification: a survey. IEEE Access. 2022;10:28642–55.
24. Mohanty C, Mahapatra S, Acharya B, Kokkoras F, Gerogiannis VC, Karamitsos I, et al. Using deep learning architectures for detection and classification of diabetic retinopathy. Sensors. 2023;23(12):5726.
25. Ahmad I, Singh VP, Agarwal S. Detection of diabetic retinopathy using deep learning-based framework. In: Machine intelligence and smart systems: proceedings of MISS 2021. Singapore: Springer Nature Singapore; 2022. p. 223–233.
26. Sushith M, Sathiya A, Kalaipoonguzhali V, et al. A hybrid deep learning framework for early detection of diabetic retinopathy using retinal fundus images. Sci Rep. 2025;15:15166. https://doi.org/10.1038/s41598-025-99309-w.
27. Senapati A, Tripathy HK, Sharma V, Gandomi AH. Artificial intelligence for diabetic retinopathy detection: a systematic review. Inform Med Unlocked. 2024;45:101445.
28. Jabbar A, Naseem S, Li J, et al. Deep transfer learning-based automated diabetic retinopathy detection using retinal fundus images in remote areas. Int J Comput Intell Syst. 2024;17:135. https://doi.org/10.1007/s44196-024-00520-w.

29. Arora L, Singh SK, Kumar S, et al. Ensemble deep learning and EfficientNet for accurate diagnosis of diabetic retinopathy. Sci Rep. 2024;14:30554. https://doi.org/10.1038/s41598-024-81132-4.
30. Alavee KA, et al. Enhancing early detection of diabetic retinopathy through the integration of deep learning models and explainable artificial intelligence. IEEE Access. 2024;12:73950–69. https://doi.org/10.1109/ACCESS.2024.3405570.
31. Jabbar A, et al. A lesion-based diabetic retinopathy detection through hybrid deep learning model. IEEE Access. 2024;12:40019–36. https://doi.org/10.1109/ACCESS.2024.3373467.
32. Rajeshwar S, Thaplyal S. Diabetic retinopathy detection using DL-based feature extraction and a hybrid attention-based stacking ensemble. Adv Public Health. 2025;2025(1):8863096.
33. Kommaraju R, Anbarasi MS. Diabetic retinopathy detection using convolutional neural network with residual blocks. Biomed Signal Process Control. 2024;87:105494.
34. Akhtar S, Aftab S, Ali O, et al. A deep learning based model for diabetic retinopathy grading. Sci Rep. 2025;15:3763. https://doi.org/10.1038/s41598-025-87171-9.
35. Muthusamy D, Palani P. Deep learning model using classification for diabetic retinopathy detection: an overview. Artif Intell Rev. 2024;57:185. https://doi.org/10.1007/s10462-024-10806-2.
36. Ait Kaci Azzou S, Boukredera D, Abiche Y, et al. Early detection and severity grading of diabetic retinopathy using fine-tuned deep learning models with automated hyperparameter optimization. SN Comput Sci. 2025;6:704. https://doi.org/10.1007/s42979-025-04250-4.
37. Chakraborty A, Wilson G, Luca C. A lightweight classification system for the early detection of diabetic retinopathy. Inf Med Unlocked. 2025. https://doi.org/10.1016/j.imu.2025.101655.
38. Nadda R, Singh J, Shrivastava U. Automatic diabetic retinopathy detection using an ensemble learning approach and classifiers with self-adjusting weights. Soft Comput. 2025. https://doi.org/10.1007/s00500-025-10773-y.
39. https://www.kaggle.com/c/diabetic-retinopathy-detection
40. https://www.kaggle.com/c/aptos2019-blindness-detection/data

Publisher's Note Springer Nature remains neutral with regard to jurisdictional claims in published maps and institutional affiliations.